

Digital Biopsy Breaking through “Visual Blind Spots”: Preoperative AI Rehearsal System for Bone Cement Leakage Based on High-Resolution Radiomics

Pan Xinyang¹, Li Minglang¹, Tang Xiaoyao¹, Liu Ranke¹, Xu Hongliang¹

¹(Zhejiang College of Construction, Hangzhou, Zhejiang, China)

ABSTRACT: Percutaneous vertebral augmentation (PVA) has been widely adopted for the treatment of osteoporotic vertebral compression fractures, yet bone cement leakage remains the most frequent and clinically occult perioperative complication. A meta-analysis of 12 cohort studies involving 2,388 patients and 3,392 vertebrae reported an overall cement leakage rate of 34%, with rates of 36% for percutaneous vertebroplasty (PVP) and 18% for percutaneous kyphoplasty (PKP). Cortical integrity disruption, intravertebral vacuum cleft, basivertebral foramen sign, and increased cement volume were identified as the most robust risk factors, with cortical defects carrying the strongest association (OR=5.00). Conventional preoperative assessment relies heavily on subjective image interpretation and fails to systematically quantify subtle cortical discontinuities, trabecular heterogeneity, and hidden low-resistance diffusion pathways—collectively defined here as “visual blind spots.” This paper proposes the concept of “digital biopsy” and presents a preoperative AI rehearsal system based on high-resolution radiomics. The system integrates automatic vertebral segmentation, standardized preprocessing, multi-dimensional radiomic feature extraction, and cement leakage risk modeling to generate individualized three-dimensional risk heat maps, leakage pathway simulations, and optimized injection strategy recommendations. The proposed framework provides a methodologically sound and clinically translatable foundation for transforming cement leakage risk from an experience-dependent judgment into a data-driven, pre-interventional decision-support process.

KEYWORDS - Bone cement leakage; Digital biopsy; High-resolution radiomics; Minimally invasive spine surgery; Preoperative AI rehearsal; Vertebral augmentation

I. Introduction

Percutaneous vertebroplasty (PVP) and percutaneous kyphoplasty (PKP) have become the primary minimally invasive treatments for osteoporotic vertebral compression fractures (OVCFs), offering rapid pain relief, restoration of vertebral stability, and shortened hospital stays. However, bone cement leakage remains a persistent and serious complication. When cement escapes through vertebral fissures, endplate defects, posterior wall disruptions, or venous channels, consequences range from local soft-tissue irritation and adjacent vertebral fractures to neural compression and pulmonary cement embolism.

A large-scale meta-analysis revealed that the overall bone cement leakage rate following PVA reached 34%, with PVP exhibiting a notably higher rate (36%) than PKP (18%). Post-operative CT scans consistently detect higher leakage rates than intraoperative fluoroscopy, underscoring the limitations of real-time monitoring alone and reinforcing the urgency of shifting risk control to the preoperative phase.

Current preoperative assessment depends predominantly on the surgeon's subjective interpretation of CT, MRI, and X-ray images. This approach is inherently limited in its ability to detect subtle cortical interruptions, occult intravertebral clefts, trabecular heterogeneity, and latent low-resistance diffusion corridors—elements we collectively term “visual blind spots.” Radiomics addresses these limitations by transforming medical images into high-dimensional quantitative data. By extracting intensity, texture, morphological, and spatial features invisible to the naked eye, radiomics enables the construction of predictive models that go beyond conventional visual assessment. Integrated with AI-based surgical rehearsal systems, this approach can simulate patient-specific cement diffusion behavior and generate actionable preoperative guidance.

II. Literature Review

2.1 Epidemiology and Risk Factors of Cement Leakage

The evidence base on cement leakage risk has matured considerably. A 2024 meta-analysis synthesizing data from 12 studies and 3,392 vertebrae identified cortical integrity disruption (OR=5.00; 95% CI: 3.01–8.29), basivertebral foramen sign (OR=1.77; 95% CI: 1.09–2.89), intravertebral vacuum cleft (OR=1.68; 95% CI: 1.07–2.65), and increased cement volume (MD=0.75 mL; 95% CI: 0.41–1.10) as the four most consistently significant

risk factors [1]. The disproportionate strength of cortical disruption—with an OR five times that of an intact vertebra—highlights the critical role of structural integrity assessment in preoperative planning.

Imaging-based preoperative prediction has also been explored. MRI studies have shown that endplate cortical defects and adjacent disc T2 signal abnormalities are significantly correlated with intradiscal cement leakage [3], suggesting that leakage is not entirely random but carries detectable anatomical precursors that can be identified before the procedure.

2.2 Radiomics in Spine Surgery

Radiomics has emerged as a promising tool for quantitative spinal imaging analysis. Published reviews confirm that radiomic features—including grey-level co-occurrence matrices, run-length matrices, shape descriptors, and wavelet-transformed intensity statistics—can reveal structural information imperceptible to the human eye [2]. In spine surgery, radiomics has been applied to vertebral fracture detection, bone quality assessment, tumour characterisation, and surgical outcome prediction [4, 5]. The core advantage lies in transforming subjective image interpretation into reproducible, quantitative metrics suitable for predictive modelling.

2.3 AI in Preoperative Spinal Planning

Artificial intelligence is rapidly expanding its role in spinal surgery planning, evolving from automatic segmentation to patient-specific 3D reconstruction and surgical simulation [6]. Recent systematic reviews indicate that machine learning-assisted modelling can substantially reduce segmentation time and improve the feasibility of personalised pre-surgical rehearsal. The “digital twin” concept further envisions patient-specific digital models driven by preoperative and real-time data, enabling AI-mediated decision support at both preoperative and intraoperative stages [7].

Table 1. Summary of Key Evidence on Bone Cement Leakage Risk Factors

Risk Factor	Effect Size	95% CI	Clinical Implication
Cortical integrity disruption	OR = 5.00	3.01 – 8.29	Strongest anatomical predictor; must be the primary modelling variable
Basivertebral foramen sign	OR = 1.77	1.09 – 2.89	Indicates venous leakage pathway; flag in 3D risk map

Risk Factor	Effect Size	95% CI	Clinical Implication
Intravertebral vacuum cleft	OR = 1.68	1.07 – 2.65	Represents low-resistance diffusion zone; prioritise spatial mapping
Increased cement volume	MD = 0.75 mL	0.41 – 1.10	Modifiable risk factor; supports individualised dosing recommendation
Overall leakage rate (PVA)	34%	—	Confirms leakage is a systematic, addressable complication
PVP leakage rate	36%	—	Higher than PKP; more stringent preoperative planning needed
PKP leakage rate	18%	—	Lower but not negligible; risk stratification still required

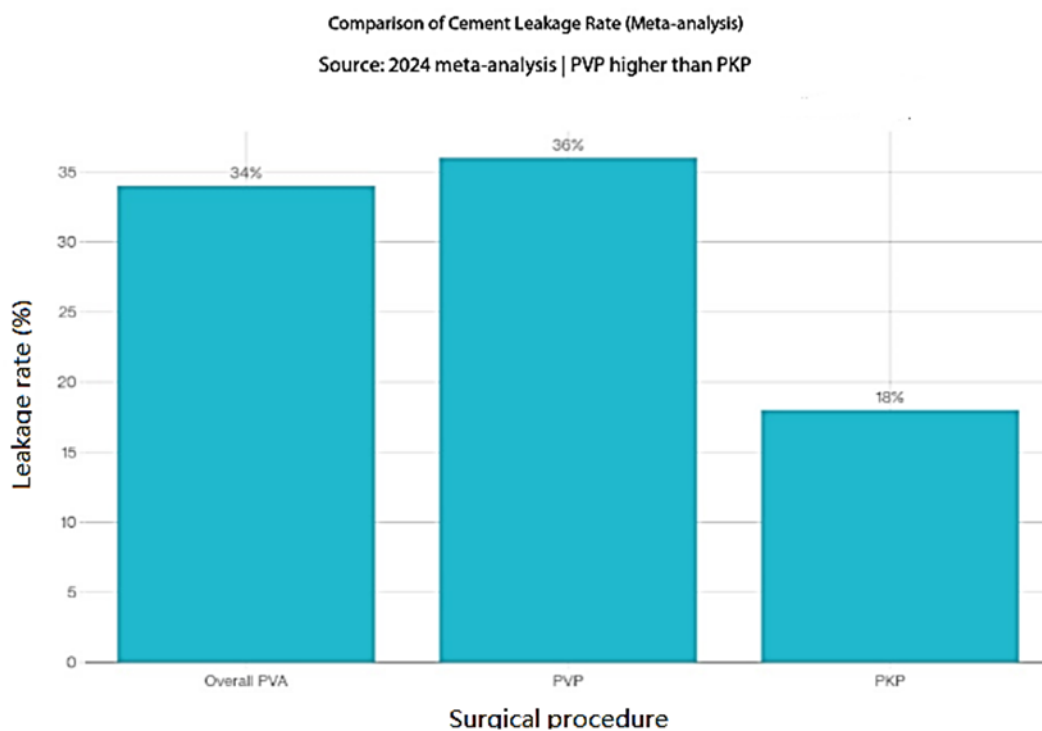


Fig. 1.

Bone cement leakage rates by surgical procedure (meta-analysis, 2024). PVP=percutaneous vertebroplasty; PKP=percutaneous kyphoplasty; PVA=percutaneous vertebral augmentation.

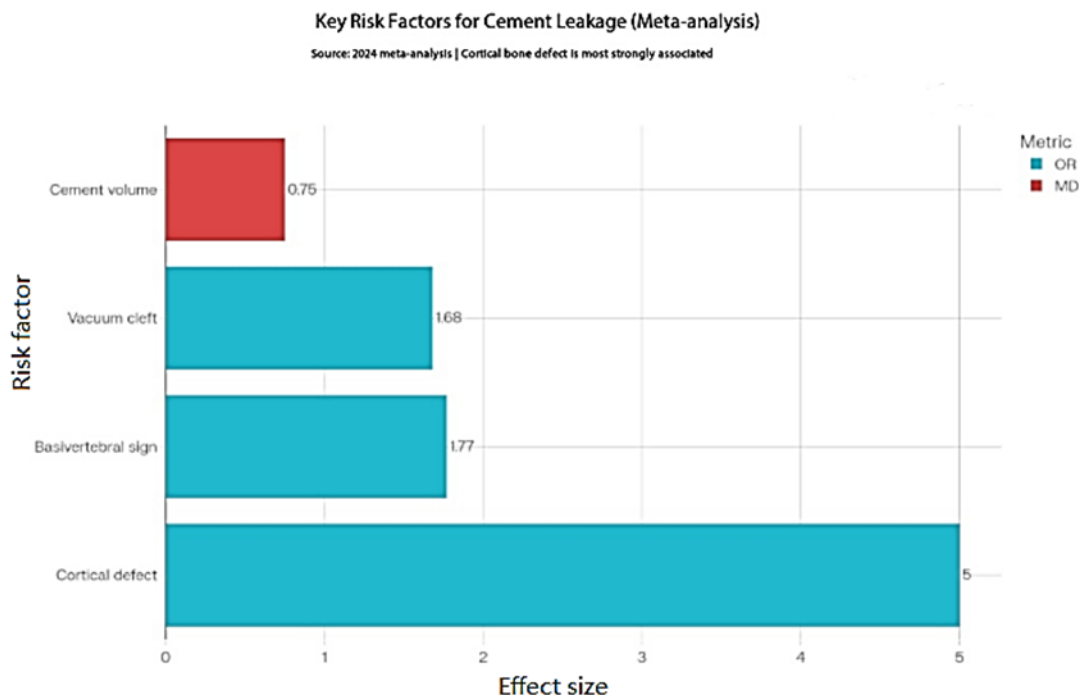


Fig. 2. Effect sizes of key bone cement leakage risk factors (meta-analysis, 2024). OR=odds ratio; MD=mean difference. Cortical defect carries the strongest association.

III. System Architecture and Methods

3.1 The “Digital Biopsy” Concept

The term “digital biopsy” is defined in this paper as a non-invasive, quantitative microstructural analysis of the target vertebra performed exclusively through high-resolution imaging. Unlike conventional image review, which asks “is there a fracture?” or “is the cortex intact?”, digital biopsy addresses the deeper clinical questions: Is the cleft connected to the endplate or posterior wall? Which direction does it orient? Does the local trabecular architecture create a preferential low-resistance diffusion zone? Where is cement most likely to escape?

This reframing transforms preoperative assessment from binary image interpretation to a multi-dimensional risk modelling exercise—one that can be systematically reproduced, quantitatively communicated, and continuously improved through feedback from surgical outcomes.

3.2 Five-Step System Pipeline

The proposed AI rehearsal system is designed as a sequential five-step pipeline:

Step 1 — High-resolution image acquisition: Thin-slice CT (≤ 1 mm slice thickness) serves as the primary input. MRI is incorporated as a supplementary source to characterise endplate signal abnormalities, T2 hyperintensity in adjacent discs, and soft-tissue involvement, all of which have established associations with leakage type and location.

Step 2 — Automatic vertebral and anatomical structure segmentation: Deep learning-based segmentation models delineate the target vertebra, pedicles, superior and inferior endplates, posterior wall, and perivertebral venous zones. Automatic segmentation reduces inter-observer variability and processing time compared to manual contouring, which is critical for clinical feasibility.

Step 3 — Image standardisation and ROI preprocessing: Standardisation protocols including denoising, resampling to isotropic resolution, and grey-level normalisation are applied to ensure cross-device reproducibility. This step is essential for training generalizable models in multi-centre datasets.

Step 4 — Radiomic feature extraction: Four categories of features are extracted from the segmented ROI: (a) morphological features—vertebral collapse ratio, endplate continuity, posterior wall integrity; (b) texture features—grey-level co-occurrence matrix (GLCM) entropy, run-length matrix heterogeneity, trabecular sparsity; (c) spatial connectivity features—cleft orientation, connectivity to cortical defect zones, venous pathway probability; (d) surgical constraint variables—anticipated cement volume and injection approach. The inclusion of anticipated cement volume is evidence-based, as increased volume is a confirmed independent risk factor [1].

Step 5 — Risk modelling and 3D visualisation output: A hybrid model combining rule-based clinical heuristics (e.g., flagging posterior wall disruption, vacuum cleft, and basivertebral sign) with machine learning ensemble methods (random forest, gradient boosting, or lightweight convolutional networks) generates a leakage probability score and spatial risk map. The output is presented as a 3D interactive visualisation showing leakage risk zones by quadrant, annotated pathway hazards, and a recommended injection parameter range.

Table 2. System Module Design and Corresponding Paper Section Framework

System Module	Core Function	Paper Section Label	Evidence Basis
Image acquisition	Thin-slice CT \pm MRI input; multi-device standardisation	Data sources & imaging protocol	MRI endplate/disc sign – leakage correlation
Automatic segmentation	Vertebra, endplates, posterior wall, venous zones	ROI definition & segmentation method	Reduces inter-observer variability

System Module	Core Function	Paper Section Label	Evidence Basis
Image preprocessing	Denoising, resampling, grey-level normalisation	Image standardisation pipeline	Required for multi-centre generalisability
Feature extraction	Morphological, textural, connectivity, surgical constraint	Radiomic feature engineering	Radiomics in spine surgery reviews
Predictive modelling	Leakage probability, risk stratification, pathway prediction	Model development & validation	Four confirmed risk factors as primary variables
Clinical output	3D risk map, injection parameters, approach optimisation	Clinical application & translational value	AI preoperative planning reviews; digital twin concept

IV. Clinical Applications and Discussion

4.1 Overcoming Visual Blind Spots

The “visual blind spot” concept captures three distinct failure modes in conventional preoperative assessment. The first is the *detection threshold failure*—small cortical interruptions below ~1 mm are routinely missed on standard CT review, yet are the strongest anatomical predictor of leakage [8]. The second is the *integration failure*—multiple sub-threshold risk signals (mild trabecular heterogeneity + slight endplate concavity + borderline vacuum cleft) are evaluated independently rather than jointly, allowing additive risk to remain invisible [9]. The third is the *spatial prediction failure*—even when individual risk signs are identified, the direction and terminus of a potential leakage pathway cannot be reliably estimated from axial slice review alone.

Digital biopsy addresses all three failure modes. Radiomic texture metrics detect cortical micro-interruptions at the sub-voxel level [10]. The predictive model integrates multi-signal risk combinations that no single heuristic captures. And three-dimensional risk mapping converts axial findings into spatial pathway predictions, enabling the surgeon to anticipate not just whether leakage might occur, but where and how.

4.2 Three-Stage Clinical Integration

The system is designed to serve across three operative stages. Preoperatively, it generates a patient-specific risk report that classifies vertebrae into low, moderate, or high risk, identifies the highest-probability leakage direction, and recommends an individualised cement volume range and approach strategy. Intraoperatively, integrated with fluoroscopic feedback, it provides real-time hazard direction alerts and dynamic injection threshold warnings. Postoperatively, comparing the actual leakage position with the preoperative risk map generates annotated training data that continuously improves model accuracy.

4.3 Limitations and Future Directions

Several challenges must be addressed before clinical deployment. First, imaging protocol heterogeneity across institutions affects radiomic feature reproducibility; standardised acquisition guidelines and harmonisation methods are prerequisite [10]. Second, bone cement leakage is partly determined by intraoperative technique variables— injection speed, needle position adjustment, cement viscosity at injection time—that cannot be captured by preoperative imaging alone. Third, without multi-centre prospective validation, model performance may not generalise beyond the training institution. Future work should prioritise prospective multi-centre cohort design, TRIPOD-compliant reporting, Radiomics Quality Score assessment, and integration of intraoperative real-time feedback loops.

V. Recommendations for Future Research

Three strategic directions are recommended for translating this framework into clinical practice. First, establish a standardised multi-centre thin-slice CT acquisition and annotation protocol to ensure training data quality and reproducibility. Second, build a stratified case library encompassing osteoporotic fractures, tumour-related vertebral lesions, complex posterior wall disruptions, and multi-level disease, covering a spectrum of risk presentations to improve model robustness. Third, embed the AI output as a unified dashboard—integrating the 3D risk map, pathway simulation, and injection parameter recommendations—directly into the surgical planning workstation to minimise adoption barriers.

VI. Conclusion

Current evidence firmly establishes that bone cement leakage is not a random event. Cortical integrity disruption, intravertebral vacuum cleft, basivertebral foramen sign, and elevated cement volume are its consistent predictors. Radiomics provides the quantitative infrastructure to detect and integrate these signals beyond the reach of conventional image review [2, 4, 5]. AI-assisted preoperative spine planning has already demonstrated the feasibility of patient-specific 3D modelling and surgical simulation [6]. The “Digital Biopsy” system proposed

in this paper—integrating high-resolution radiomics, automatic segmentation, multi-dimensional feature engineering, and 3D risk rehearsal—offers a systematic pathway from experiential risk avoidance to data-driven pre-interventional decision support. Its implementation has the potential to meaningfully raise the safety ceiling of minimally invasive spinal augmentation surgery.

Acknowledgements

This project is supported by the Zhejiang Province University Students Science and Technology Innovation Activities Plan (Xinmiao Talent Program) for the year 2026.

References

- [1.] Risk factors for cement leakage after percutaneous vertebral augmentation for osteoporotic vertebral compression fractures: a meta-analysis. *J Orthop Surg Res*. 2024. PMC11745741.
- [2.] Alsoof D, McDonald CL, Durand WM, et al. Radiomics in Spine Surgery. *Int J Spine Surg*. 2023;17(Suppl 1):S57–S64. doi:10.14444/8501.
- [3.] Cement leakage during vertebroplasty can be predicted on preoperative MRI. *AJR Am J Roentgenol*. 2007;188(3):735–741.
- [4.] Lambin P, Rios-Velazquez E, Leijenaar R, et al. Radiomics: extracting more information from medical images using advanced feature analysis. *Eur J Cancer*. 2012;48(4):441–446.
- [5.] Gillies RJ, Kinahan PE, Hricak H. Radiomics: images are more than pictures, they are data. *Radiology*. 2016;278(2):563–577.
- [6.] Artificial Intelligence in Planning for Spine Surgery. *PMC*. 2025. PMC12446165.
- [7.] Digital twin assisted surgery, concept, opportunities, and challenges. *npj Digit Med*. 2025. doi:10.1038/s41746-024-01413-0.
- [8.] CT evaluation of local leakage of bone cement after percutaneous vertebroplasty and kyphoplasty. *J Vasc Interv Radiol*. 2010;21(2):175–179.
- [9.] Risk factors for cement leakage and nomogram for predicting cement leakage after percutaneous vertebroplasty. *PMC*. 2020. PMC7702672.
- [10.] van Timmeren JE, Cester D, Tanadini-Lang S, et al. Radiomics in medical imaging — how-to guide and critical reflection. *Insights Imaging*. 2020;11:91.